



CASE REPORT

Unexpected Histopathological Finding: A Case report of *Schistosoma* Ova in Prostate Adenoma

Kura MM,^{1,2} Ibrahim R,^{3,4} Damina MM,⁵ Lawan AI.^{5,6}

¹ Department of Surgery, Gombe State University, Gombe

² Department of Surgery, Federal Teaching Hospital, Gombe

³ Department of Community, Gombe State University, Gombe

⁴ Department of Community, Federal Teaching Hospital, Gombe

⁵ Department of Histopathology, Federal Teaching Hospital, Gombe

⁶ Department of Histopathology, Gombe State University, Gombe.

Keywords

Prostate adenoma,

Prostatectomy,

Schistosoma ova,

ABSTRACT

Background: Schistosomiasis of the gastrointestinal and urinary tracts is well-known, yet its chronic effect on host genitalia such as the prostate is often ignored or overlooked. This report describes an incidental finding of *Schistosoma* ova in a prostate adenoma.

Case: A 66-year-old man from a schistosomiasis endemic area in northeastern Nigeria presented with symptoms of bladder outlet obstruction. The Prostate-specific antigen (PSA) was normal, and he had no family history of prostate cancer. Histopathology of the prostate adenoma removed at open prostatectomy had multiple foci of acute and chronic inflammation with calcified *Schistosoma* ova and areas of luminal abscesses, and there were no foci of malignancy. A diagnosis of prostate adenoma with schistosomiasis was made.

Conclusion: Genital schistosomiasis should be a differential diagnosis of prostate pathologies, especially in patients who live in or have recently visited schistosomiasis endemic communities.

Correspondence to:

Ibrahim Rabi

Department of Community, Gombe State University, Gombe

Email: ibrahimrabi69@gmail.com

INTRODUCTION

Different species of the genus *Schistosoma* cause schistosomiasis in humans.¹ This disease frequently leads to irreversible damage in the bladder and liver, contributing to the significant morbidity burden in regions where schistosomiasis is prevalent.² Over 700 million

people are at risk of contracting schistosomiasis, with about 200 million of them living in sub-Saharan Africa.³⁻⁵ About 95.2 million adults' population are estimated to be at risk of schistosomiasis.² The two species endemic in Nigeria are *Schistosoma Haematobium* and *Schistosoma Mansoni*. Regarding mortality,

Schistosoma Haematobium is considered less significant than *Schistosoma Mansoni*. However, it can lead to other health issues, including cancer, and its coexistence with diseases like HIV and cancer can result in increased mortality rates.² Daily, the adult worm of *Schistosoma Haematobium* produces hundreds to thousands of ova.⁶ Most of these eggs are excreted in the urine, but some ova may penetrate and lodge in the tissues of the bladder, bowel and, to a lesser extent the genital organs such as the prostate gland, seminal vesicles, vas deferens, spermatic cord and the penis causing a disease entity called male genital schistosomiasis (MGS).^{7,8}

Prostatic (male genital) schistosomiasis (MGS) is rarely reported. In 1993, Cohen et.al. identified dormant and active schistosome ova in the prostate and seminal vesicles of approximately 15% of all males between the ages of 3 months to 70 years in an autopsy study from Southern Africa.⁹ Additionally, in 1973, Edington et al. in Nigeria reported cases of genital schistosomiasis, including prostatic (MGS), from autopsy studies at University College Hospital in Ibadan.¹⁰ The body forms granulomas due to inflammation in the genitals in response to the entrapped schistosome eggs, causing genital lesions.¹¹ The genital lesions may lead to sequelae that could directly or indirectly cause other chronic pathologies. *Schistosoma Haematobium* and *Schistosoma Mansoni* associated prostate pathologies have been reported in different schistosomiasis endemic African countries, Brazil, and also schistosomiasis non-endemic

areas like USA and Iraq.¹²⁻¹⁵ Thus, though scanty, available literature reports a possible association of schistosomiasis with the development of chronic prostatic pathologies particularly, in schistosomiasis-endemic areas. This case report aims to describe an uncommon case of schistosomiasis associated with adenoma of the prostate from a peripheral hospital in Northeastern Nigeria. It highlights the presence of *Schistosoma* ova in the prostate tissue of a patient who had open prostatectomy for bladder outlet obstruction secondary to benign prostatic enlargement. The ova indicate previous or ongoing schistosomal infection, which was not clinically apparent.

CASE REPORT

A 66-year-old male farmer had experienced bladder outlet obstruction symptoms (urinary frequency, dysuria, urinary hesitancy and straining to urinate) for more than a year. Despite medication, his symptoms progressively worsened. He reported a history of terminal haematuria from childhood but reported no instances of haematospermia, urethritis, urethral procedures, or trauma to the perineal or pelvic areas. Additionally, no constitutional symptoms were present, he has no family history of prostate cancer, and he is married with children.

The key clinical findings on digital rectal examination were an enlarged, non-tender prostate that was firm, with a smooth outline and loss of the median groove. An abdominal ultrasound scan showed an enlarged prostate with a volume of 42.7cm³. The capsule was normal

and had a heterogeneous parenchymal echo-pattern. The prostate-specific antigen (PSA) was 2.02 ng/ml. He had prostatectomy and the histology report confirmed nodular hyperplasia of the prostate with calcified ova of *Schistosoma haematobium* some of which show terminal spine, there are stromal lymphocytic infiltrates and adjacent hyperplastic glands as shown in

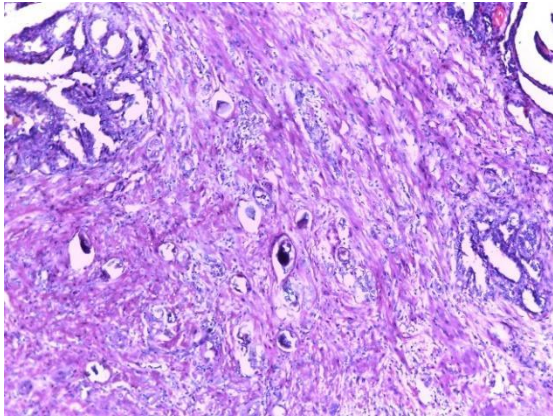


Figure 1: H&E x40: Photomicrograph of the prostate showing calcified ova, some of which show terminal spine as seen in *Schistosoma haematobium*. There are stromal lymphocytic infiltrates. Adjacent hyperplastic glands are noted.

DISCUSSION

Finding *Schistosoma* ova in a prostate adenoma presents a unique and intriguing case, highlighting the intersection of infectious disease and oncology. Schistosomiasis, caused by parasitic worms of the genus *Schistosoma*, is a significant public health concern in endemic regions, particularly in Africa, Southeast Asia, and South America.¹⁶ While the involvement of the bladder by *Schistosoma Haematobium* is well-documented, its presence in the prostate,

Figures 1 and 2, confirming a diagnosis of male genital schistosomiasis. The patient was given praziquantel at a dose of 40mg/kg and the patient reported significant improvement in his presenting symptoms during the subsequently follow-up.

The permission of the patient was sought, and he willingly agreed to have the findings published.

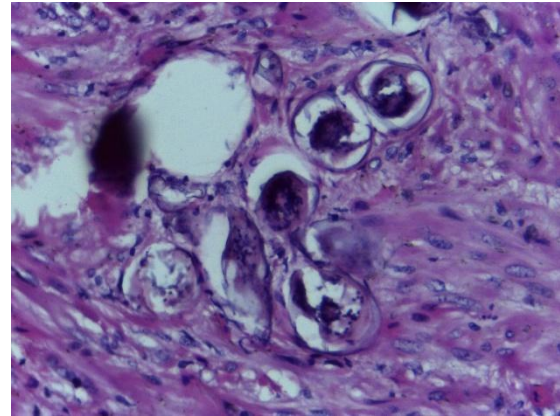


Figure 2: H&E x400: Photomicrograph showing calcified *Schistosoma* ova

especially within an adenoma, is not as common and is noteworthy.

The presence of *Schistosoma* ova in the prostate can lead to chronic inflammation, which may contribute to the development or exacerbation of prostatic diseases. Chronic inflammation is a known risk factor for various malignancies, including prostate cancer.¹⁷ In this case, the patient's history of residence in a schistosomiasis-endemic area likely contributed to the parasitic infection. The chronic

inflammatory response induced by the *Schistosoma* ova could have exacerbated the lower urinary tract symptoms.

The diagnosis of schistosomiasis in the prostate is challenging due to its atypical presentation. The digital rectal examination, as described earlier, combined with a PSA of 2.02 ng/ml, was in keeping with bladder outlet obstruction secondary to benign prostate enlargement, and the patient was offered an open prostatectomy. The recurrent prostatic inflammation from schistosoma-induced prostatitis can cause elevation of PSA¹⁸, as seen in this patient, and this could have exposed the patient to unnecessary prostate biopsy with its attendant complications. Thus, Prostatic (male genital) schistosomiasis can have a varied presentation. In this case, the discovery was incidental during histopathological examination of the prostate adenoma. This underscores the importance of thorough histopathological evaluation in patients from endemic regions presenting with urological symptoms. The use of advanced imaging techniques and molecular diagnostics could aid in the early detection of such rare presentations

The management of schistosomiasis in the prostate involves treatment with agents such as praziquantel, which is effective against *Schistosoma* species.¹⁹ In addition to antiparasitic therapy, addressing the underlying prostatic condition, such as bladder outlet obstruction secondary to benign prostatic enlargement, as in this patient. In this patient, an open prostatectomy was done considering the patient's age and

clinical presentation. The patient was also treated with praziquantel at a dose of 40mg/kg.

One of the strengths of this report is that the finding can serve as a basis for further research into the interactions between parasitic infections and prostate adenoma, potentially offering new insights into disease processes. Since this is a rare finding, generalizing management approaches or outcomes from a single case may not be possible, limiting the relevance of the finding to broader clinical practice.

This case highlights the need for increased awareness and screening for schistosomiasis in endemic regions, especially among patients presenting with urological symptoms. Public health initiatives aimed at controlling schistosomiasis through improved sanitation, access to clean water, and mass drug administration are essential in reducing the burden of this disease.¹⁶

CONCLUSION

Although rare, the incidental finding of *Schistosoma* ova in prostate adenoma during histological examination of tissues from open prostatectomy, is an important reminder of the diverse presentations of schistosomiasis. It emphasizes the need for heightened awareness among clinicians and pathologists, particularly in regions endemic to schistosomiasis. Further studies are warranted to understand such findings' implications and improve the management and outcomes of affected patients.

Conflict of interest: The authors declare no conflict of interest.

REFERENCES

1. Colley DG, Secor WE. Immunology of Human Schistosomiasis. *Parasite Immunol.* 2014; 36(8): 347-357. doi:10.1111/pim.12087
2. World Health Organisation. Epidemiology Table of Schistosomiasis Current Estimated Total Number of Individuals with Morbidity and Mortality due to Schistosomiasis Haematobium and S. Mansoni Infection in Sub-Saharan Africa. 2019 <http://www.who.int/schistosomiasis/epidemiology/table/en/>.
3. Adenowo AF, Oyinloye BE, Ogunyinka BI, Kappo AP. Impact of Human Schistosomiasis in Sub-Saharan Africa. *Braz J Infect Dis.* 2015; 19(2): 196-205. doi: 10.1016/j.bjid.2014.11.004
4. Umar MA, Umar AU, Usman ID, Yahaya A, Dambazau SA. Schistosoma Haematobium Infections: Prevalence and Morbidity Indicators in Communities around Wasai Dam, Minjibir, Kano state, and Northern Nigeria. *Inter J of Trop Disease & Health.* 2016; 17(2): 1–8. doi: 10.9734/IJTDH/2016/23448
5. Kjetland EF, Hegertun IE, Baay MF, Onsrud M, Ndhlovu PD, Taylor M. Genital Schistosomiasis and its Unacknowledged Role on HIV Transmission in the STD Intervention Studies. *Int J STD AIDS.* 2014; 25(10): 705-715. doi:10.1177/0956462414523743
6. World Health Organisation. Cancer Country Profiles 2014. <https://www.who.int/cancer/country-profiles/en/>. Accessed 17 August 2024.
7. Mbabazi PS, Andan O, Fitzgerald DW, Chitsulo L, Engels D, Downs JA. Examining the Relationship between Urogenital Schistosomiasis and HIV Infection. *PLoS Negl Trop Dis.* 2011; 5(12): e1396. doi: 10.1371/journal.pntd.0001396
8. Feldmeier H, Leutscher P, Poggensee G, Harms G. Male Genital Schistosomiasis and Haemospermia. *Trop Med Int Health.* 1999; 4(12):791-793. doi:10.1046/j.1365-3156.1999.00511.x
9. Cohen RJ, Edgar SG, Cooper K. Schistosomiasis and Prostate Cancer. *Pathology.* 1995; 27(2): 115-116. doi:10.1080/00313029500169682
10. Edington GM, von Lichtenberg F, Nwabuebo I, Taylor JR, Smith JH. Pathologic Effects of Schistosomiasis in Ibadan, Western State of Nigeria. I. Incidence and Intensity of Infection; Distribution and Severity of lesions. *Am J Trop Med Hyg.* 1970 Nov; 19(6): 982-95. doi: 10.4269/ajtmh.1970.19.982.
11. Stecher CW, Kallestrup P, Kjetland EF, Vennervald B, Petersen E. Considering Treatment of Male Genital Schistosomiasis as a Tool for Future HIV Prevention: a Systematic Review. *Int J Public Health.* 2015; 60(7): 839-848. doi:10.1007/s00038-015-0714-7
12. Figueiredo JC, Richter J, Borja N, et al. Prostate Adenocarcinoma Associated with Prostatic Infection due to Schistosoma Haematobium. Case Report and Systematic Review. *Parasitol Res.* 2015; 114(2): 351-358. doi:10.1007/s00436-014-4250-9
13. Basílio-de-Oliveira CA, Aquino A, Simon EF, Eyer-Silva WA. Concomitant Prostatic Schistosomiasis and Adenocarcinoma: Case Report and Review. *Braz J Infect Dis.* 2002; 6(1): 45-49. doi:10.1590/s1413-86702002000100007
14. El-Hawary AK, Foda AAM. Incidentally Detected Schistosomiasis in Male Genital Organs: Case Reports and Review of Literature. *Am J Cas. Rep.* 2016; 4 (1): 25–30.
15. Metrogos V, Ramos N, Marialva C, Bastos J. Rare Association between Prostate Adenocarcinoma and Schistosomiasis: A Case Report. *ACTA Urológica Portuguesa.* 2017; 34(3–4): 41–3 doi: <https://doi.org/10.24915/aup.34.3-4.45>
16. Chohan KR, Kling CA, Byler TK. *Schistosoma Haematobium* Ova in Human Semen: A Case Report. *F S Rep.* 2020 Oct 24; 2(1): 126-128. doi: 10.1016/j.xfre.2020.10.004.
17. Mukendi AM, Doherty S, Ngobese L. Schistosomiasis on Prostate Biopsy, Adenocarcinoma on Transurethral Resection of Prostate Specimens. *Journal of Clinical Urology.* 2020; 13(6): 451-453. doi:10.1177/2051415819889203

18. Nepal A, Sharma P, Bhattarai S, Mahajan Z, Sharma A, Sapkota A, Sharma A. Extremely Elevated Prostate-Specific Antigen in Acute Prostatitis: A Case Report. *Cureus*. 2023 Aug 18; 15(8): e43730. doi: 10.7759/cureus.43730.
19. Hailegebriel T, Nibret E, Munshea A. Efficacy of Praziquantel for the Treatment of Human Schistosomiasis in Ethiopia: A Systematic Review and Meta-Analysis. *J Trop Med*. 2021 Dec 20; 2021: 2625255. doi: 10.1155/2021/2625255